

# COOL RENEWAL<sup>®</sup> CASE STUDY

**Veterinarian Name:** Dr. Steven Barta

**Practice Name:** Veterinary General, Shelby Township, Michigan

**Date of Treatment:** May 6, 2016– June 6, 2016

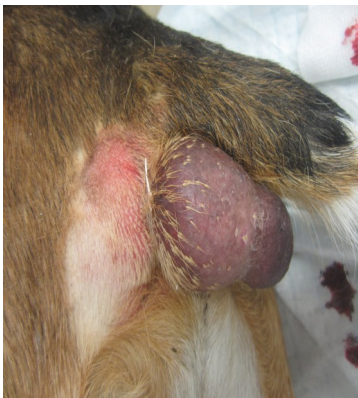## Treatment Summary

Breed: Beagle, Age: 9 Years, 1 Month, Weight: 49.9 lbs, Neutered,

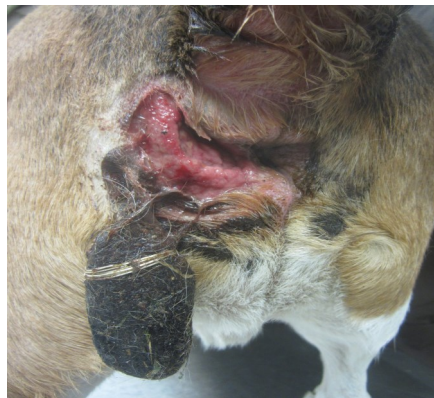Not a candidate for anesthesia.

~ 1 x 2.5 centimeter soft mass protruding from the left side of rectum

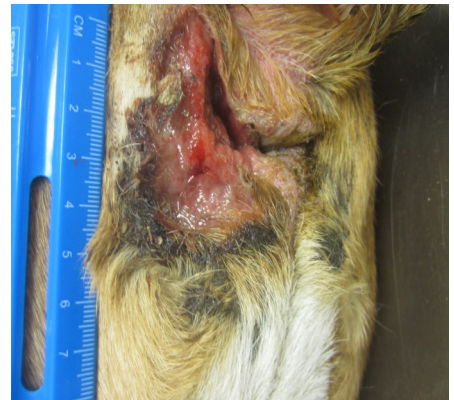Patient was nervous- administered 40mg of Benadryl, 0.6 mls of DexDomitor IV. Shaved and prepped area in a sterile manner. Injected Lidocaine at the base of the stalk. Ligated with 2 Braunamide sutures at the base of the mass. Applied Vaseline to the edge of the isolation funnel before applying to skin to prevent leakage. Sprayed entire mass and base with Cool Renewal cryogen several times . Administered 0.89 mls of Metacam 5mg, & 0.6 mls Antisedan IM– Follow up every week for 6 weeks.



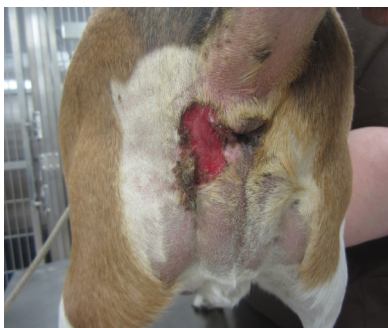Ligated Mass — May 6, 2016



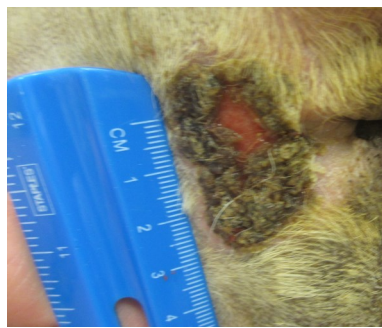Necrotized Mass– May 13, 2016



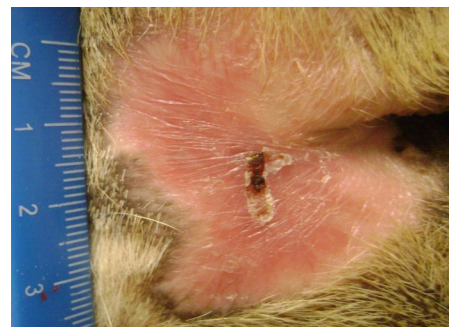
Skin after mass removal– May 13, 2016



Healing Skin– May 20, 2016



Healing Skin– May 26, 2016



New Skin Growth & Healing June 10, 2016