


COOL RENEWAL®

Case Study

January, 2015

Provided by: Dr. Marc Smith, DVM, CVA- Nashville, TN



Signalment: a 10-year-old male castrated Bull Mastiff

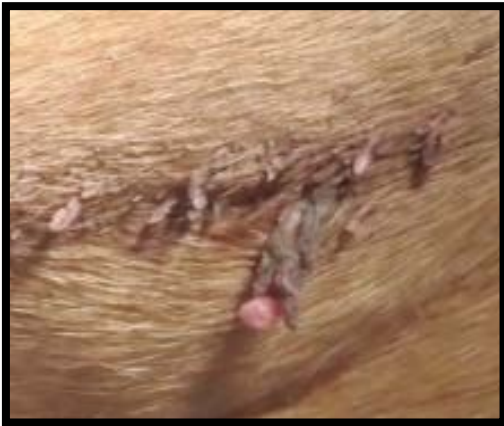Chief complaint: The chief reason for seeking veterinary attention is the fact that this dog has numerous skin tags located on the sternum and also between the hind legs. Rarely, the skin tags will bleed usually due to self-mutilation or excessive licking. Bleeding presents a problem for the owner as much of the blood is spread on the carpet and throughout the house.

Solution: Generally, in my practice, I would recommend surgical removal of these lesions. Although this dog is a candidate for surgery, I think a better option might be some sort of conservative treatment considering his age and the fact that he is an anesthetic risk. For these cases, I typically use liquid nitrogen and freeze the small skin lesions for complete resolution. My problems with typical cryosurgery surgery units are the cost and the storage of liquid nitrogen.

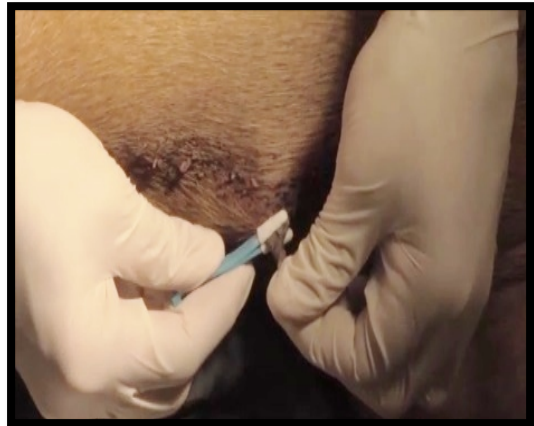Results/opinion: The cool renewal system allows for quick, cost effective resolution of small skin lesions and skin abnormalities without the use of sedation and or general anesthesia. The system is easy to use and the package insert adequately explains the product and the usage of the product in different scenarios. I think the system affords an easy opportunity to remedy small, benign skin lesions in a cost effective, user friendly, client compliant manner.

COOL RENEWAL®

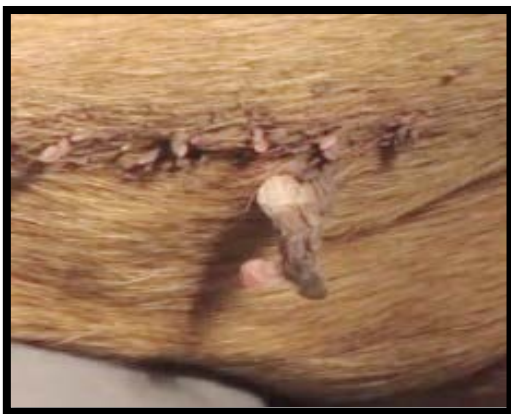Treatment Results



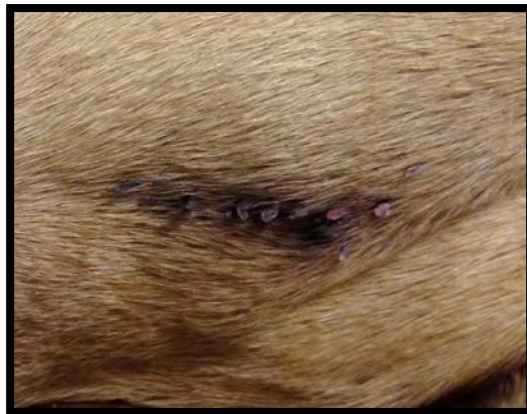**Skin Tag
Before Treatment**



**Skin Tag being frozen at the base
with Skin Tag Tweezers,
eliminating blood supply to tag.**



**Frozen base of tag immediately
after application of cryogen.**



**45 Days After
Treatment**

To view the complete treatment video, please visit <http://www.cool-renewal.com/demonstration-video.html>